

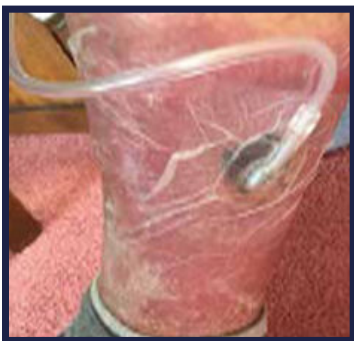

Disposable NPWT System Case Studies Chronic Leg Ulcer and Pressure Injury

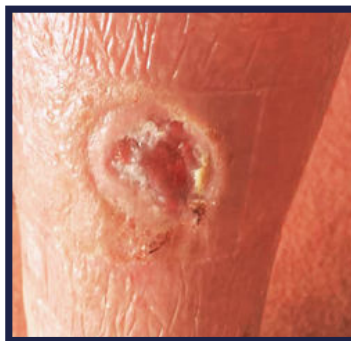CASE 1 - Chronic Leg Ulcer

An 89-year-old male presented with a chronic leg ulcer of 4 months duration without healing. Comorbidities include heart disease causing swelling in the limbs, and aplastic anemia. The NEXA™ NPWT System was used to apply negative pressure treatment to the wound.

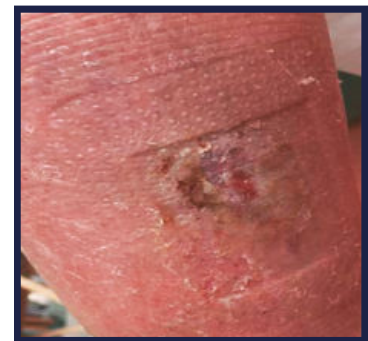
The wound size decreased markedly over the treatment period. At day 39 the wound was too small to continue with the NEXA System. The wound progressed to full closure within the next week using standard wound care.



NEXA Dressing in situ



Day 19 of treatment



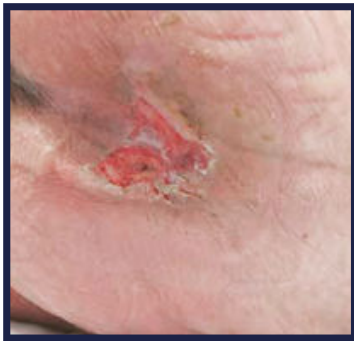
Day 39 of treatment

"These case studies were important for three reasons. The simplicity of use, effectiveness of the treatment and associated cost which are all important to modern wound healing. This particular pump (NEXA System) was found to be very successful in all 3 areas and the healing of the [2] wounds that healed, given their chronicity, was remarkable."

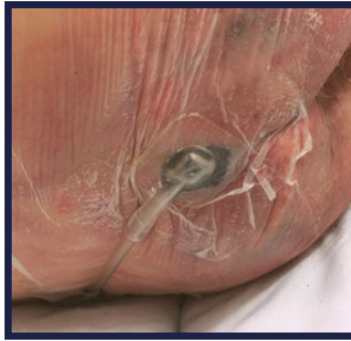CASE 2 - Pressure Injury

This case involves an 84-year-old female with multiple sclerosis. She has poor nutrition as she refuses food. She is on long-term bedrest and has developed a pressure injury over the sacrum of 3 months duration.

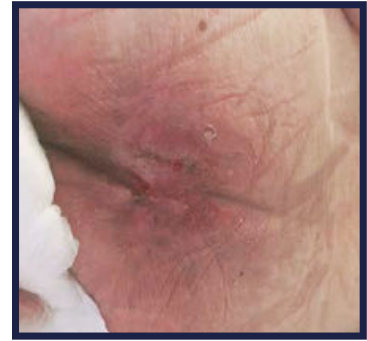The NEXA System was applied when the wound measured 2.5cm x 3.0cm (Day 1 photo). By day 10 of treatment, the wound had shrunk to such a degree that the NEXA System could no longer be applied. Of note, was a second wound that developed and was also treated with the NEXA System and was discontinued after only one week.



Day 1 of treatment



NEXA Dressing in situ



Day 10 of treatment

"The NEXA NPWT System is an excellent product. It has the advantages of being simple to use and inexpensive when compared to other products. Overall, every nurse enjoyed using the NEXA System and the patient, who had experience with other NPWT systems (and hated the thought of using it due to the alarm constantly waking her) was grateful for the fact the NEXA System did not wake her once, the therapy pump noise did not disturb her in the least and the wound is certainly in a healing state."



AOTI Ltd. Unit 20, Glenrock Business Park, Ballybane, Galway. Ireland.
Email: internationalsales@aotinc.net

Case photos, patient information and quotes provided by Sylvie Hampton and Sarah Gray (Independent Tissue Viability Nurse Consultants, Hailsham, UK)

Visit www.NEXANPWT.com for more information



414-10-006